Angiographically Non Significant Coronary Lesions Giving Rise To Acute Myocardial Infarction Later In Life, *Two Case Reports.*

Elbagir Elbasheer MD[1], Hajer M. K. Alhadie MD[2]

Key words:

Non significant coronary lesions, acute myocardial infarction, percutaneous coronary intervention

1/ consultant interventional cardiologist, Sudan Heart Centre, Sudan

Email for correspondence: elbagire@gmail.com

2/Cardiology Fellow, Sudan Heart Centre

Introduction:

Severely stenotic coronary lesions (70% and more luminal stenosis) are usually indicated for dilatation and stenting especially in symptomatic patients. While lesions of mild to moderate stenosis are usually left alone and treated with optimum medical therapy. These mildly stenotic lesions represent the vast majority of lesions encountered during routine and emergency coronary catheterization[1] and also those lesions giving rise to plaque rupture and acute myocardial infarcion. This evidence-based practice of stenting severely stenotic lesions only, however, did not translate into reduction of mortality and long term prognosis of patients with coronary artery disease[2,3]. Most coronary events which are directly related to mortality and morbidity in fact arise mostly from non severely stenotic lesions[4]. Interventional cardiology usually addresses these severely stenotic lesions and ignores the minor ones. This practice would probably explain part of the failure of stenting to improve the overall patient's prognosis.

In this case report, we described two patients with mildly stenotic lesions that are (appropriately) left alone, but resulting in an AMI several months later.

Case 1:

44 yrs old gentleman, presented with inferior STEMI (Fig1), and received thrombolytic therapy. Elective coronary angiography few days later showed (Fig2, 3): RCA: (the culprit artery) has already canalized and stenosis severity was only modest. The LAD showed also a non significant stenosis in its mid part. In both lesions it was rightly felt that stenting was not indicated and optimized medical therapy alone was decided. Hospital stay was unremarkable and patient was discharged home for outpatient follow up. 6 months later, he was put to the exercise treadmill machine and managed to achieve a work level of 13 Mets and reached 89% of target heart rate. No angina or ECG changes reported (Fig4). During follow up he reported enjoying good functional capacity without any limiting symptoms. Two years later he presented with acute chest pain, his ECG showed St Elevation in the anterior leads (Fig5). He was immediately shifted to the cath lab for primary PCI. At the cath lab, the RCA lesion showed no progression of the degree of stenosis compared to previous degree of stenosis(Fig6). Injection of the left system revealed a tight stenosis (99%) in the mid LAD exactly at the site of the previously non significant lesion (Fig7).The mid LAD lesion was stented successfully.

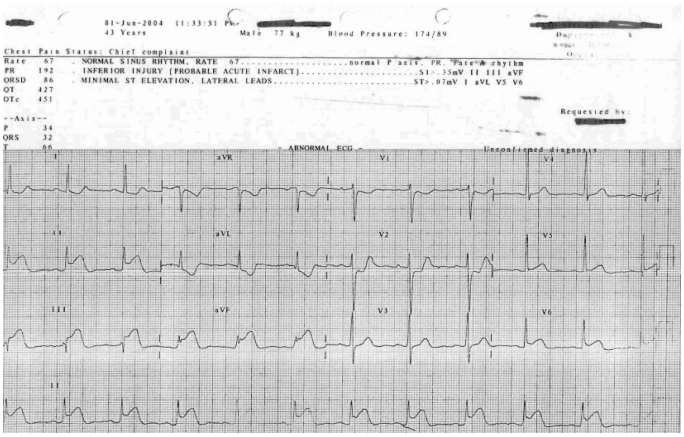

Figure 1

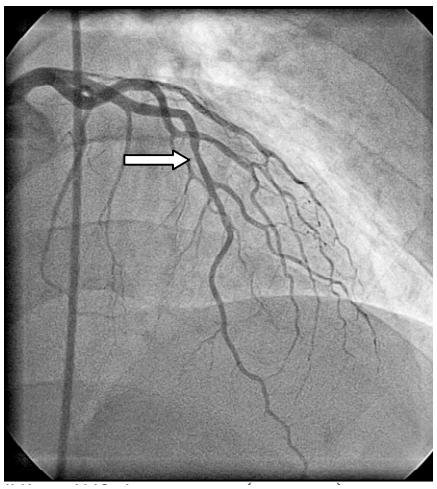

Figure 2(arrow points to the mild LAD lesion)



Figure3(canalized RCA, the culprit lesion)

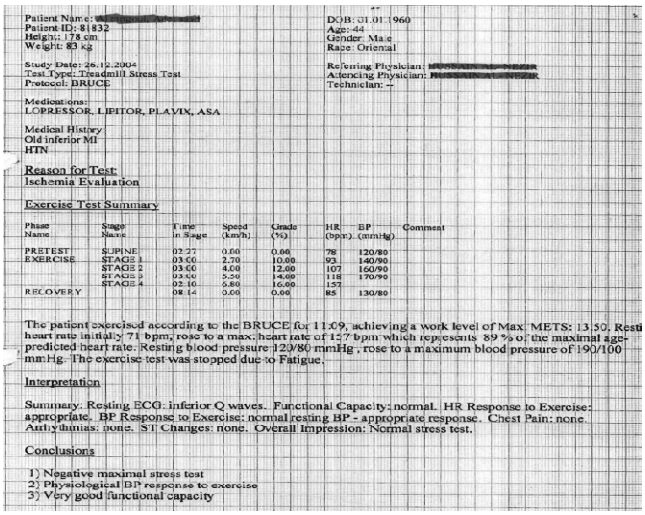

Patient Name: [redacted]
Patient ID: 81832
Height: 178 cm
Weight: 83 kg

DOB: 01.01.1960
Age: 44
Gender: Male
Race: Oriental

Study Date: 26.12.2004
Test Type: Treadmill Stress Test
Protocol: BRUCE

Referring Physician: [redacted]
Attending Physician: [redacted]
Technician: --

Medications:
LOPRESSOR, LIPITOR, PLAVIX, ASA

Medical History
Old inferior MI
HTN

Reason for Test:
Ischemia Evaluation

Exercise Test Summary

Phase Name	Stage Name	Time in Stage	Speed (km/h)	Grade (%)	HR (bpm)	BP (mmHg)	Comment
PRETEST	SUPINE	02:27	0.00	0.00	78	120/80	
EXERCISE	STAGE 1	03:00	2.70	10.00	93	140/80	
	STAGE 2	03:00	4.00	12.00	107	160/90	
	STAGE 3	03:00	5.20	14.00	118	170/90	
	STAGE 4	02:10	5.80	16.00	153		
RECOVERY		08:14	0.00	0.00	85	130/80	

The patient exercised according to the BRUCE for 11:09, achieving a work level of Max METS: 13.50. Resti heart rate initially 71 bpm, rose to a max heart rate of 157 bpm which represents 89 % of the maximal age-predicted heart rate. Resting blood pressure 120/80 mmHg , rose to a maximum blood pressure of 190/100 mmHg. The exercise test was stopped due to Fatigue.

Interpretation

Summary: Resting ECG: inferior Q waves. Functional Capacity: normal. HR Response to Exercise: appropriate. BP Response to Exercise: normal resting BP - appropriate response. Chest Pain: none. Arrhythmias: none. ST Changes: none. Overall Impression: Normal stress test.

Conclusions

1) Negative maximal stress test
2) Physiological BP response to exercise
3) Very good functional capacity

Fig4(negative treadmill test 6 months post mi)

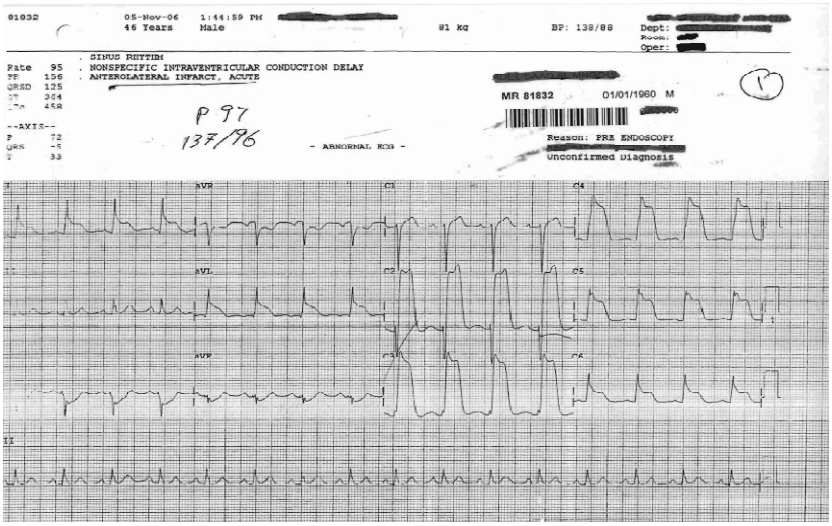

Fig 5



Fig 6

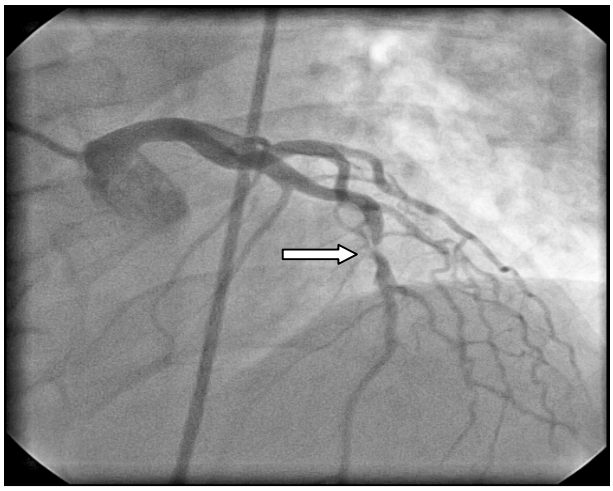

Fig 7 tight mLAD (arrow)

Case2

50 years old gentleman was referred to our center for coronary angiogram 2 month after he had sustained an inferior STEMI for which he was successfully thrombolysed. His coronary angiography showed normal Lt system. The PDA branch of the RCA showed a minor irregularity at its mid segment followed successively by an area of 30% stenosis (Fig8). Optimum medical therapy was prescribed and intervention was felt not to be indicated. Hospital stay was unremarkable with good resolution of the St Elevation in the inferior leads and normal left ventricular function on echocardiography. During regular outpatient follow up for two years he enjoyed symptom free life with good exercise capacity. 2 years later the patient presented again to our hospital with severe acute chest pain. His admission's ECG showed ST

elevation in the inferior leads (Fig 9). The patient was taken to the cath lab for primary PCI. Injection of the RCA revealed a 99% stenosis of the proximal PDA lesion (the site of the irregularity) while the stenosis severity of the lesion distal to it remained the same (Fig 10). It was obvious that the culprit lesion this time was the subtotally occluded proximal lesion, which was subsequently dilated and stented with good angiographic result. (Fig 11)

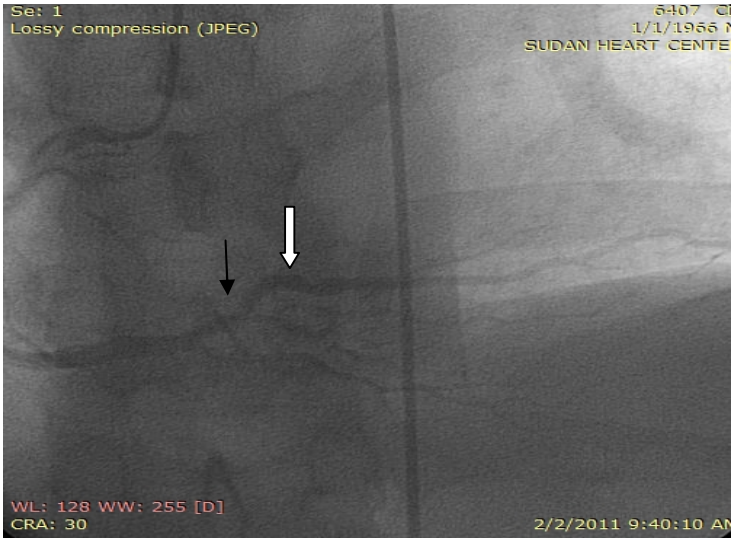

Figure 8(mild irregularity (black arrow) followed by mild stenosis(white arrow)

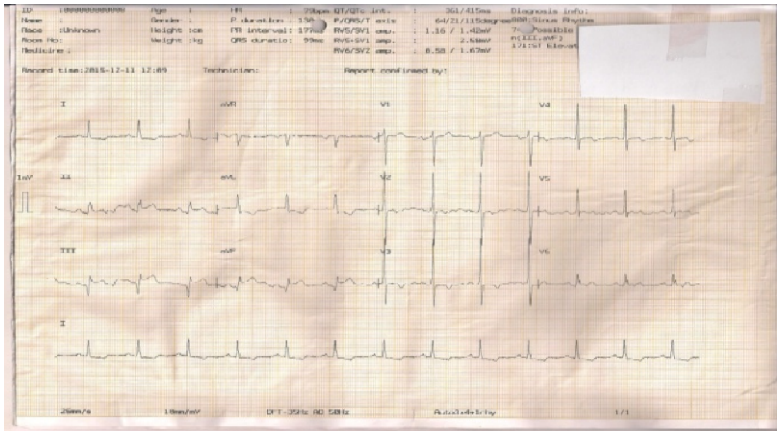

Fig 9

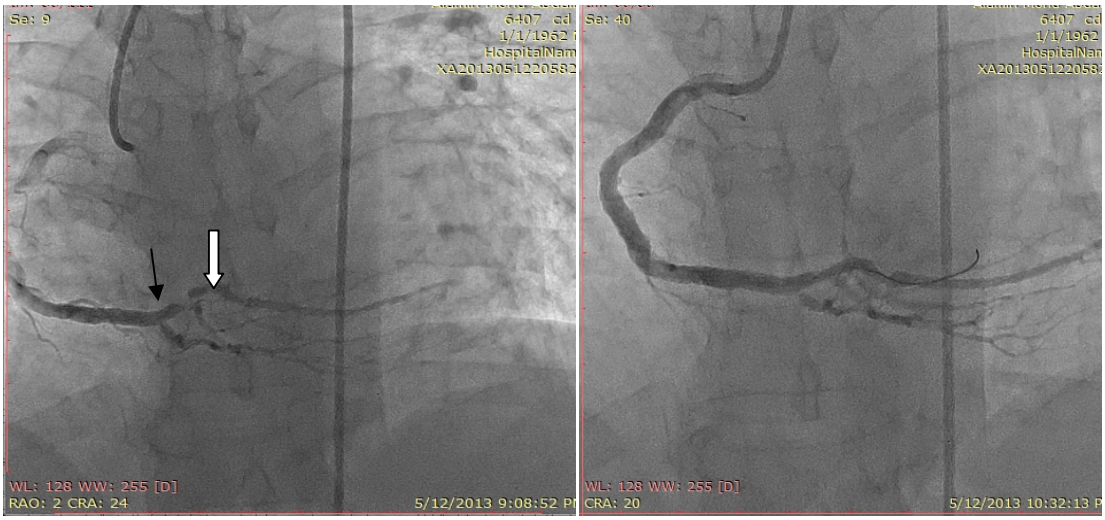

Figure10 Fig 11

Discussion:

These two patients showed two lesions that were modestly stenotic initially but ruptured two years later resulting in two serious cardiac events. While in the same two patients, two lesions that had ruptured and canalized

satisfactorily (post thrombolysis and/or spontaneously) remained quite stable and dormant for a long period of time without any mechanical intervention. This raises important questions of whether leaving these modestly stenotic lesions at the time when they pose a signicant risk of plaque rupture resulting in myocardial infarction any time later in life. It is true, that stenting these mildly stenotic lesions with the currently available metallic stents is a too aggressive treatment and associated with a risk almost equal to the risk of plaque rupture in these patients. It seems that other options should be discussed like a controlled and elective balloon rupture (a form of plaque sealing) to artificially rupture these plaques in hospital under cover of bets medical therapy and allowing later on healing to stabilize could be an option that need to be addressed [5]. More over the need for less aggressive stents and scaffolds may be required to treat such mildly stentic lesions. Resorabable and biodegradable stents are probably a valid treatment option.

Future studies should focus on the outcome of these mildly stenotic lesions and their impact on long term prognosis. There is also a call for an optimum therapy, either medically or mechanically, to stabilize such lesions and improve their future outcome.

References:

1/ Erling *et al*, Circulation; 1995:92:657-671

2/ William E. *et al*. COURAGE Trial, N Engl J Med 2007; 356:1503-1516

3/ Hochman *et al*; Occluded Artery Trial. N Engl J Med. 2006 Dec 7;355(23):2395-407.

4/Cutlip, D. E. et al. Circulation 2004;110:1226-1230

5/ Meier *et al*., *Heart 2004;90;1395-1398*

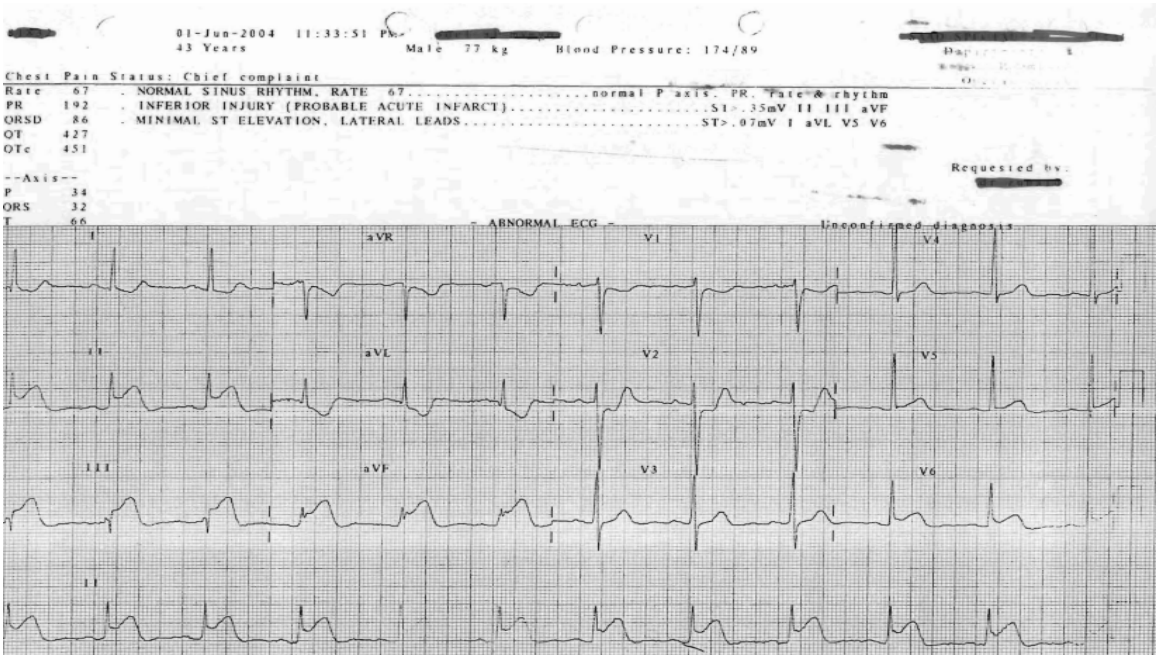
01-Jun-2004 11:33:51
43 Years
Male 77 kg
Blood Pressure: 174/89
Chest Pain Status: Chief complaint
Rate 67
PR 192
QRSD 86
QT 427
QTc 451
--Axis--
P 34
QRS 32
T 66
. NORMAL SINUS RHYTHM, RATE 67.....normal P axis. PR, rate & rhythm
. INFERIOR INJURY (PROBABLE ACUTE INFARCT).....S1>.35mV II III aVF
. MINIMAL ST ELEVATION, LATERAL LEADS.....ST>.07mV I aVL V5 V6
Requested by:
- ABNORMAL ECG -
Unconfirmed diagnosis
I
aVR
V1
V4
II
aVL
V2
V5
III
aVF
V3
V6
II