CASE REPORT

Images of right atrial mass with Inferior vena cava extension.

Ahmed Suliman, MBBS, FACP, FESC, Hajer Elhadie, MBBS, MRCP (UK)

Faculty of Medicine, University of Khartoum

Case history

A 65 year old male with biopsy proven renal cell carcinoma (RCC) of the right kidney was referred for echocardiogram for pre-operative assessment. An incidental right atrial mass was found on echocardiogram. The mass appears rounded with smooth surface and homogenous echogenicity with no attachment to the interatrial septum. The mass (M) measured 4.7 cm x 3.5 cm and clearly extended into the inferior vena cava (IVC) distal to the hepatic veins (Images 1-4)

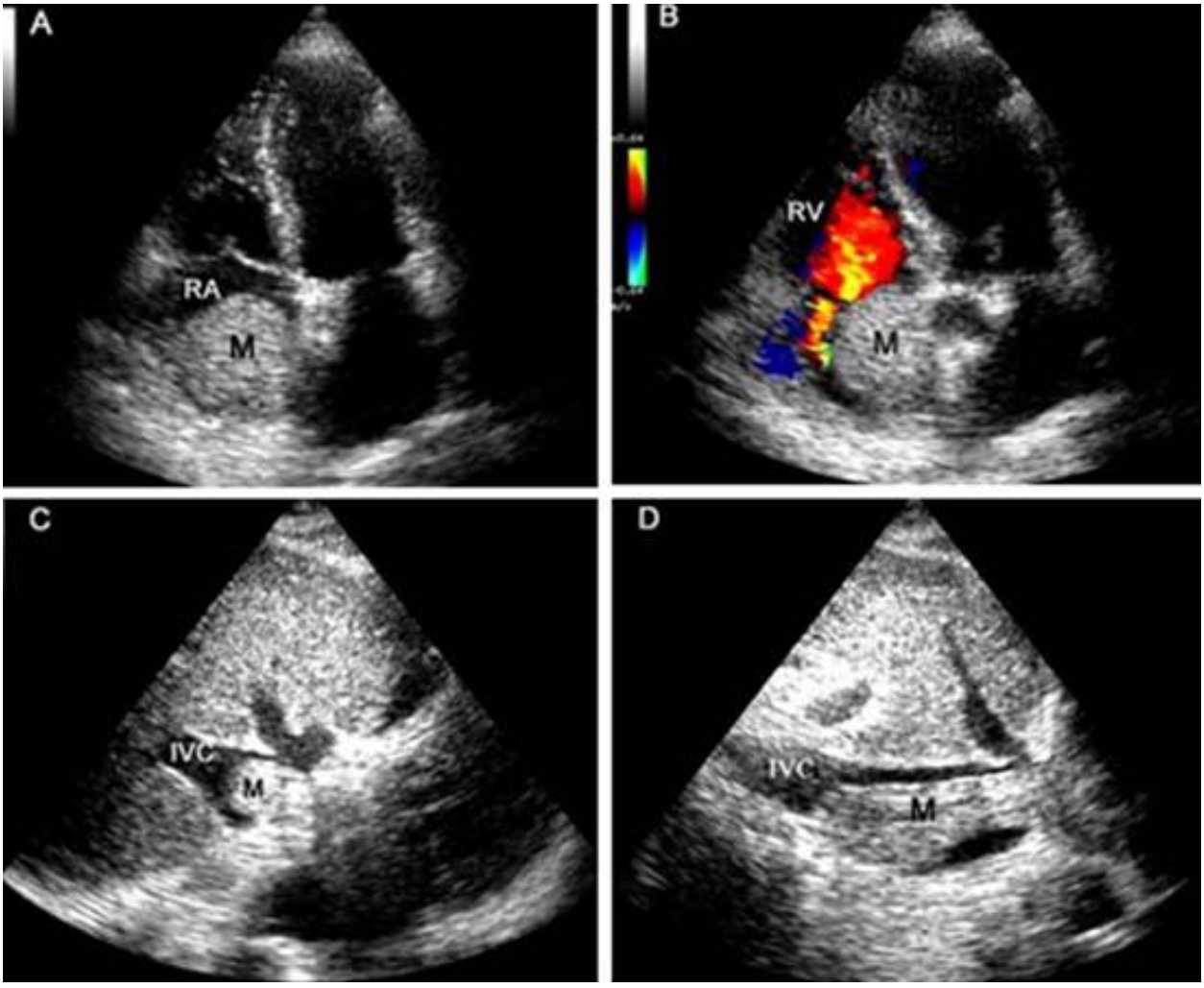

Panel A. Four chamber apical view showing a rounded right atrial homogenous mass with smooth outline. Panel B. Four chamber apical view with color Doppler showing normal flow around the mass Panel C. Modified subcostal view showing the atrio-caval junction with the mass protruding from right atrium into inferior vena cava. Panel D. Subcostal longitudinal view of the inferior vena cava (IVC) showing the mass occupying the IVC beyond the hepatic vein.

Review and discussion:

Cardiac masses generally are detected incidentally in imaging tests done for unrelated indication, though cardiovascular or constitutional symptoms may be present. Vegetation, thrombi and tumors are the most common causes of cardiac masses. Tumors are usually malignant and metastatic from other sites with primary tumors of the heart being rare. They are usually benign with myxoma being the most frequent. Malignant primary tumors of the heart are exceedingly rare.[1][2]

For isolated right atrial masses, the two main differential diagnoses are thrombi and atrial myxoma. However, other possibilities including prominent Eustachian valve or Chiari network, pacemaker wires, balloon or central line catheters, cysts, giant mobile interatrial septal aneurysm and ultrasound artifacts have to be considered [3]. However, when there is an IVC extension of the mass the main etiologies would be transvenous extension of malignant tumors especially RCC ([1] or transvenous extension of peripheral thrombi which are usually worm-like in appearance and confer significant risk of pulmonary embolism These are type A thrombus according to the European Cooperative study on clinical significance of right heart thrombi [4].

In a series of 75 patients with cardiac tumors referred for surgery nine patients had RA masses with IVC extension. Seven had RCC, one had hepatocellular carcinoma and one rhabdomyoma [5]. Adrenocortical carcinoma, testicular sarcoma, intravenous leiomyomatosis and melanoma also reported [6][7]. Such tumors may also be a combination of malignant tissue and thrombus and MRI with gadolinium contrast can differentiate bland thrombus from combined thrombus and tumor with latter showing heterogeneous enhancement and the former not [8].

In our case the mass appears solid, homogenous with smooth margin, and with IVC extension and background of RCC, transvenous extension of the malignancy is most likely. Transesophageal echo was not performed in our case , but has a role in better mass visualization especially in patients with poor echo windows and is important to delineate any tumor attachment to the inter-atrial septal wall [3] [6].

RCC with atrial extension only constitute 1% of all cases of RCC [9][10] .For such tumors extending into intra-cardiac structures, a holistic approach is required involving radiologist, anesthesiologist, urologist and cardiothoracic surgeon. The use of cardiopulmonary bypass is required for safe and complete excision of renal cell carcinoma extending to the intracardiac structures and involves nephrectomy, cavotomy and atriotomy with tumor removal [11] [12].

References:

(1)Bruce C J. Cardiac tumors: diagnosis and management. Heart 2011;97:151-160 doi:10. 1136/hrt.2009.186320

(2)Gowda RM, Khan IA, Nair CK, et al. Cardiac papillary fibroelastoma: a comprehensive analysis of 725 cases. Am Heart J 2003;146:404e10.

(3)Moluk Mirrasouli Ragland, DO and Tahir Tak, MD, PhD. The Role of Echocardiography in Diagnosing Space-Occupying Lesions of the Heart Clin Med Res. 2006 Mar; 4(1): 22–32.

(4) The European Cooperative Study on the clinical significance of right heart thrombi. European Working Group on Echocardiography. Eur Heart J. 1989 Dec;10(12):1046-59.

(5) Dujardin KS, Click RL, Oh JK. The role of intraoperative transesophageal echocardiography in patients undergoing cardiac mass removal. J Am Soc Echocardiogr. 2000 Dec;13(12):1080-3.
(6) Weyman A. Right ventricular inflow tract. In Principles and Patterns of echocardiography (edited by: Weyman AE) Lea and Febiger, a Waverly Co. Second edition 1994; 824-62.
(7) Araki E, Koide Y, Fujimoto K, Okazaki K. Intravenous leiomyomatosis with extension into the right atrium: differential diagnosis from right atrial myxoma by intraoperative transesophageal echocardiography. Masui. 2008 Aug;57(8):1008-12.
(8) Sparrow P.J., Kurian J.B., Jones T.R., et al; MR imaging of cardiac tumors. Radiographics. 2005;25:1255-1276.
(9) Glazer AA, Novick AC. Long-term follow up after surgical treatment for renal cell carcinoma extending into the right atrium. J Urol 1996;155:448-450.
(10) Babu SC, Mianoni T,Shah PM, Goyal A, Choudhury M, Eshghi M, Moggio RA, Sarabu MR, Lafaro RJ
. Malignant renal tumor with extension to the inferior vena cava. Am J Surg 1998;176:137-139.
(11) Schimmera C, Hilligb F, Riedmillerb H and Elerta O. Surgical treatment of renal cell carcinoma with intravascular extension. Interact CardioVasc Thorac Surg (2004) 3 (2): 395-397.doi: 10.1016/j.icvts.2004.02.014
(12) Chiappini, B., Savini, C., Marinelli, G., Suarez, S.M., Di Eusanio, M., et al. Cavoatrial tumor thrombus: single-stage surgical approach with profound hypothermia and circulatory arrest, including a review of the literature. J ThoracCardiovascSurg 2002; 124: 684-688.