CASE REPORT

Thrombus in transit across patent foramen ovale in sinus rhythm in the absence of structural heart disease and coagulation abnormalities.

Hani Abuelgasim (H Abuelgasim), MRCP(UK), MRCPE, Cardiology Clinical Fellow, Warwick Hospital, United Kingdom. (former Cardiology Registrar, Prince Sultan Cardiac Center Hofuf, Saudi Arabia). **Corresponding author**: dr.hani@sudamedica.com Mohamed Ali Mohmed (M A Mohamed), MRCP(UK), Cardiology Registrar, Prince Sultan Cardiac Center Hofuf, Saudi Arabia.

Abstract:
A young patient, with no significant past medical history, presented with rapidly progressive breathlessness and syncope. Echocardiography revealed bilateral atrial masses and a massively dilated right ventricle (RV). Computed Tomography Pulmonary Angiogram (CTPA) confirmed sub-massive pulmonary embolism. Transoesophageal echocardiogram showed thrombus in transit across a patent foramen ovale (PFO). Treatment of pulmonary embolism with anticoagulation led to resolution of the pressure overload on the RV and both atrial masses, confirming the diagnosis of thrombus in transit. This is a rare diagnosis in patients with sinus rhythm in the absence of structural heart disease and coagulation abnormalities.

Case History

A 40-year-old gentleman presented to Emergency Department with a one week history of progressive dyspnoea on exertion associated with palpitation, dizziness and an episode of syncope. He was a current smoker with a 20 pack-year history of smoking. There was no other significant past medical or family history.

On physical examination; blood pressure was 130/70mmHg, a regular pulse was regular, rapid at a rate of 120 beats per minute, with normal character and volume. Pulse oximetry revealed oxygen saturation of 95% on room air. Cardiovascular examination revealed an elevated jugular venous pressure, there was no abnormal or added heart sounds. Chest examination revealed normal breath sounds, and there was no peripheral oedema or stigmata of infective endocarditis. There was no neurological deficit and no clinical signs of Deep Vein Thrombosis (DVT), purpura or clotting disorders.

Initial blood results showed a random glucose of 437.4 mg/dl, hemoglobin of 17.5 g/dL and D-Dimer was 2.85ug/mL (normal range: less than 0.5ug/mL). Blood count, coagulation, renal and liver profiles were within normal limits. Chest x-ray (PA film) showed prominent hilar vasculature (figure 1A). Electrocardiogram (ECG) showed sinus tachycardia at rate of 112 per minute, $S_1Q_3T_3$ pattern with incomplete right bundle branch block (figure 1B). Trans-Thoracic Echocardiogram (TTE) revealed preserved Left Ventricular (LV) systolic function, a severely dilated right ventricle (RV) and biatrial masses protruding through both atrioventricular valves into ventricles with each atrial systole like cheer pom poms (figure 2A, 2B). Pulmonary Artery Systolic Pressure (PASP) was estimated at 48 mmHg. Symptoms, ECG, D-Dimer and

echocardiographic findings established the diagnosis of Pulmonary Embolism (PE). CT Pulmonary Angiogram confirmed sub-massive bilateral Pulmonary Embolism. Low Molecular Weight Heparin (LMWH); Enoxaparin 1mg/kg/dose twice daily was administered.

For further evaluation, Trans-Oesophageal Echocardiography (TOE) confirmed echogenicity and morphology favouring thrombi over myxomas. It also revealed thrombus in transit across a patent foramen ovale (PFO) (figure 3A, 3B). Lower limb venous Doppler study did not show any evidence of DVT. Seven days after anticoagulation a repeat TTE showed resolution of the thrombus and RV recovery to its normal size. Thrombophilia screen was carried out; protein C and protein S were normal and factor V Leiden (functional APC resistance assay) was not detected. Antinuclear antibody, anti-proteinase 3 and anti-myeloperoxidase were all negative. Patient had a smooth recovery and was discharged on Warfarin.

Figure 1A

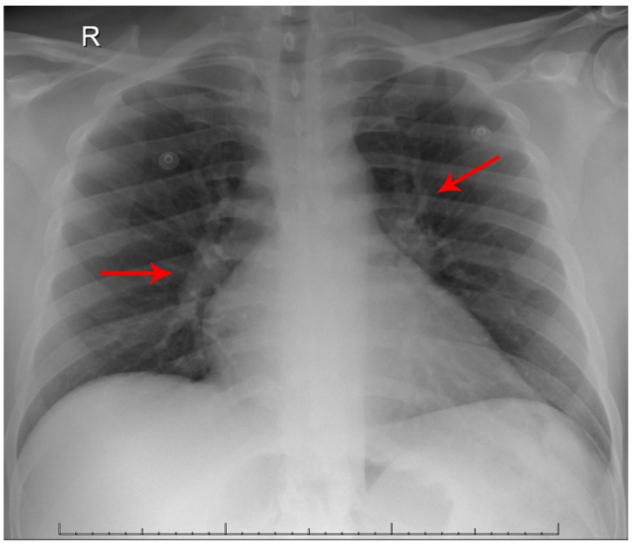

Chest x-ray (PA view) showing clear lung fields, prominent hilar vasculature bilaterally (arrows)

Figure 1B

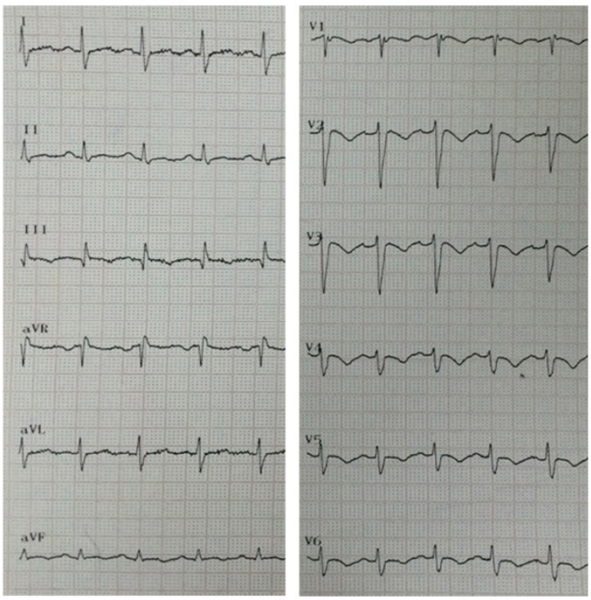

ECG: sinus rhythm, rate: 112bpm, S1 Q3 T3 with incomplete RBBB, QRS duration 90ms

Figure 2A

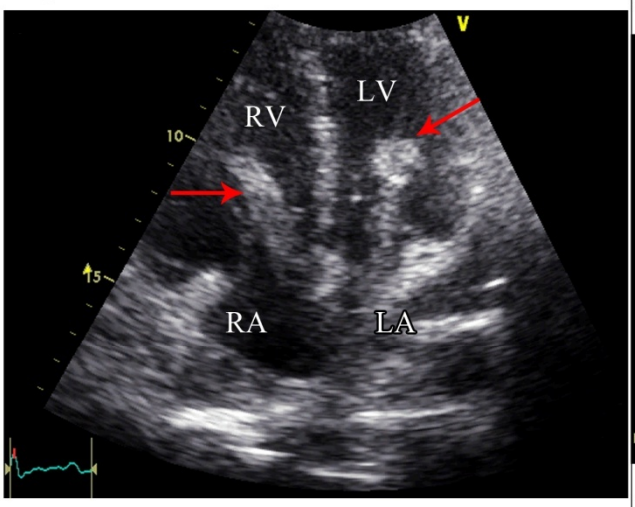

Echo-A4CV showing biatrial masses protruding through both atrioventricular valves (arrows), RV though not fully delinated appears dilated.

RV: right ventricle. LV: left ventricle. LA: left atrium. RA: right atrium. A4CV: Apical 4 chambers veiw

Figure 2B

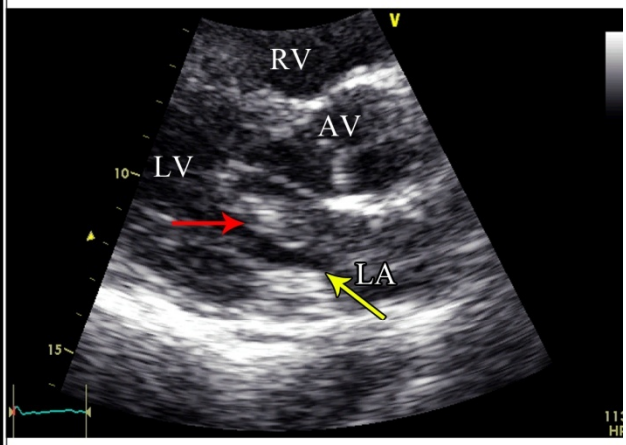

Echo-PLAX (zoomed) showing left atrial mass (red arrow) protruding through open mitral valve (yellow arrow).

RV: right ventricle. LV: left ventricle. LA: left atrium. AV: aortic valve. PLAX: parasternal long axis view

Figure 3A

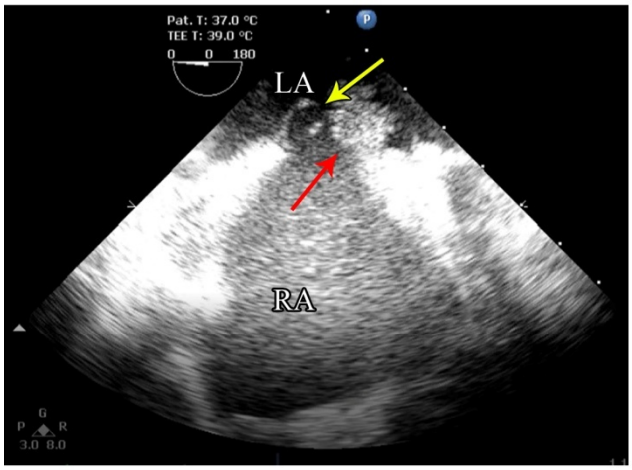

TOE mid-oesophageal view showing PFO (yellow arrow) and thrombus (red arrow) sliding into left atrium.

RA: right atrium. LA: left atrium. PFO: patent foramen ovale. TOE: trans-oesophagel echocardiogram

Figure 3B

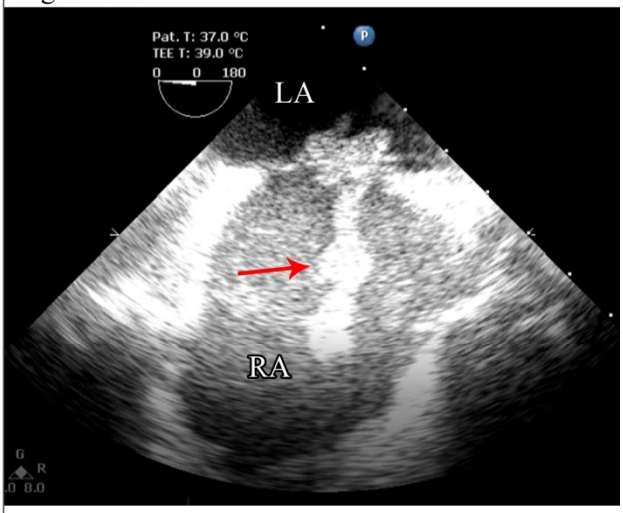

TOE mid-oesophageal view showing thrombus (red arrow) in right atrium, attached to intra-atrial septum with extension of thrombus into left atrium.

RA: right atrium. LA: left atrium. TOE: trans-oesophagel echocardiogram

Discussion:

Intra-atrial thrombi are more common than atrial myxomas (1) but the incidence of atrial thrombi in sinus rhythm is quite rare (2). A case of biatrial thrombi in presence of sinus rhythm has been reported in 1987 in a lady in her 60s who happened to have evidence of venous thromboembolism, the migration of the thrombus to the left heart was through the presence of PFO (3). Another case of biatrial thrombi in sinus rhythm has been reported in a patient with idiopathic restrictive cardiomyopathy with concomitant DVT precipitated by orthpaedic surgery (4). A young lady with Klippel-Trenaunay syndrome (predisposition for thromboembolism) had recurrent PEs and systemic embolization through PFO (5).

Generally, the likelihood of thrombus in sinus rhythm is 0.1% (2). We are reporting a rare case of biatrial thrombi in sinus rhythm with no echocardiographic evidence of cardiomyopathy and no evidence of predisposition to thromboembolism, although absence of DVT at the time of scan does not completely rule its presence at one time previously

Despite bilateral atrial thrombi and sub-massive PE, there was no indication for fibrinolysis (6) (7) (8) patient had a smooth course with no systemic embolization and a fairly quick and complete recovery with no long-term sequelae. The recovery of RV size after the resolution of PE was reassuring and confirmative that RV dilatation was caused by pressure overload secondary to PE. Closure of PFO was not considered in this case with idiopathic thrombus formation.

Conclusion: Intra-atrial thrombi can occur with no prior predisposing structural cardiac or coagulation abnormalities

References

1. Burke A, Jeudy J, Jr, Virmani R. *Cardiac tumours: an update: Cardiac tumours.* 94, s.l. : Heart, 2008, Vols. 117-123.

2. Agmon Y, Khandheria BK, Gentile F, Seward JB. *Clinical and echocardiographic characteristics of patients with left atrial thrombus and sinus rhythm: experience in 20 643 consecutive transesophageal echocardiographic examinations.* 2002, Circulation (AHA Journal), p. 105(1):27.

3. Cazzani E, Benvenuto M, Muzio L. *Pulmonary and systemic embolism in a case of biatrial thrombosis. Role of two-dimensional echocardiography.* Dec;17, s.l. : Giorn Ital Cardiol, 1987.

4. Okan Turgut, Kenan Yalta, Mehmet Birhan Yilmaz, Rafet Dizman, Izzet Tandogan. *Free-floating biatrial thrombi with concomitant saddle pulmonary embolism.* 144, s.l. : Int J Cardiol., 2010.

5. Chow V, Wang W, Wilson M, Yiannikas J. *Thrombus in transit within a patent foramen ovale: an argument for consideration of prophylactic closure?* Feb;40(2), s.l. : J Clin Ultrasound, 2012, Vols. 115-8.

6. Perrier, Christophe Marti Gregor John Stavros Konstantinides Christophe Combescure Olivier Sanchez Mareike Lankeit Guy Meyer Arnaud. *Systemic thrombolytic therapy for acute pulmonary embolism: a systematic review and meta-analysis.* 36 (10): 605-614, 2014.

7. Michael R. Jaff, M. Sean McMurtry, Stephen L. Archer et al. *Management of Massive and Submassive Pulmonary Embolism, Iliofemoral Deep Vein Thrombosis, and Chronic Thromboembolic Pulmonary Hypertension.* 123:1788-1830, s.l. : Circulation (AHA Journal), 2011.

8. *British Thoracic Society Standards of Care Committee Pulmonary Embolism Guideline Development Group. 58:470-483, 2003.*